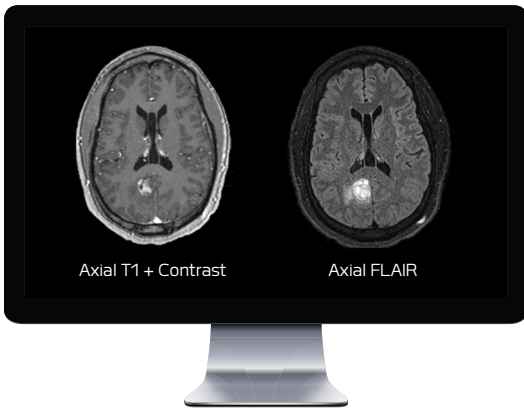

# HIGH GRADE GLIOMA

GUSTAVO PRADILLA, MD

CHIEF OF NEUROSURGERY SERVICE, GRADY MEMORIAL HOSPITAL



## CLINICAL PRESENTATION

The patient is a 38-year-old male, who presented with a history of seizures from a known left parietal parasagittal mass diagnosed by imaging criteria as a likely glioma. He was followed radiographically and within 5 years the lesion increased in size, and the patient's seizure disorder progressed, requiring increased anti-epileptic doses. The patient also had a history of migraines, which were managed with medication.

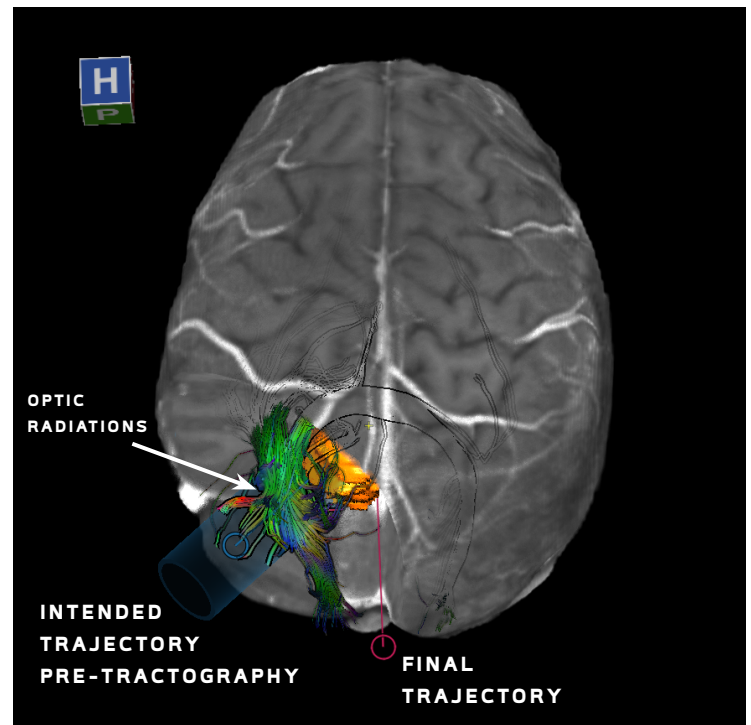
The patient underwent a pre-operative MRI including anatomical imaging (left) and DTI. Whole brain tractography data was generated using BrightMatter™ Plan, a surgical planning tool used to automatically generate tractography data.

## SURGICAL PLAN

Based on the location of the tumor, the optic radiations were expected to be displaced and expose a corridor for surgical access; however, BrightMatter™ Plan tractography revealed that the optic radiations were not displaced as expected, meaning that a corridor for surgical access was not available (right). Therefore, the patient was positioned laterally with the left side down and a stereotactic bilateral occipital open craniotomy with an inter-hemispheric approach parallel to the falx cerebri was chosen instead.

## SURGICAL MANAGEMENT

After the plan was imported to neuronavigation, the location of the tumor was identified and resected. The tumor boundary was determined once the optic radiation was reached laterally, and the corpus callosum was reached anteriorly.



Tractography revealed that the optic radiations were not displaced by the tumor (orange) as expected, therefore, an inter-hemispheric open approach (pink trajectory) was chosen over a corridor approach (blue trajectory).

## CLINICAL OUTCOMES

The surgery went as planned, and the patient had no new deficits after surgery, including no changes in his Humphreys automated fields, confirming preservation of his optic radiations.

## CASE HIGHLIGHTS

- BrightMatter™ Plan revealed that the optic radiations were not displaced by the pathology as expected
- Based on the tractography data, the surgeon chose an inter-hemispheric open approach with the patient positioned left side down, over a corridor surgery
- No visual deficit observed post-operatively